

Knee Injury: Weight Training

Gaurav S. Majmudar, MD, MPH

PM&R PGY-3, Sinai Hospital of Baltimore in Association with the University of Maryland School of Medicine

Neel Patel DO; Jordan Wickstrom PhD

ABBEL Research Division, Rehabilitation Institute at Sinai, Sinai Hospital of Baltimore, Baltimore, MD

Samuel T. Dona Jr, MD, CAQSM, FAAPMR

Assistant Professor of Neurology and Orthopaedics, University of Maryland School of Medicine

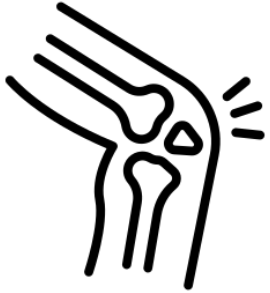DISCLOSURE

I have no financial disclosure or conflicts of interest with the discussed material in this presentation

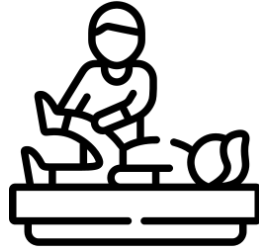Chief Complaint

A 31-year-old male noted persistent right knee pain during descent on compound lower extremity movements while participating in CrossFit workouts.

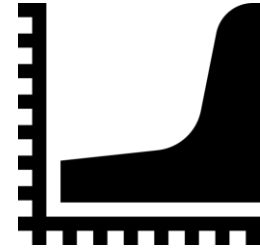
CASE HISTORY



Symptoms began several months ago without any inciting injury or history of trauma



Patient initially attributed pain to CrossFit and weight training, and enrolled in PT



2 months of PT provided some relief, but he noted a plateau in improvement which led him to present to our sports medicine clinic

PAIN HISTORY

Location/ Radiation	R Anterior Knee	Exacerbating Factors	Exercise
Quality	Sharp	Pertinent Prior Surgeries/Injections	None
Pain Score	5/10	Current Pain Medications	OTC NSAIDs
Alleviating Factors	Rest, Knee Sleeves	Locking, Clicking or Swelling or Buckling	None

FOCUSED PHYSICAL EXAMINATION

BMI: 28.25 kg/m² (Ht 6' 2' in., Wt. 220.0 lb) ; Vital Signs within normal limits

- Patient in no acute distress, non antalgic walking gait
- 5/5 strength in bilateral hip flexors, hip abductors, and in knee flexion/extension

RIGHT KNEE

- No obvious effusion or gross deformity
- Normal alignment in standing position
- No tenderness to palpation of medial and lateral joint lines, patella
- **Mild pain with medial and lateral patellar facet loading**
- **Mild tenderness with palpation over the proximal patellar tendon and compression of Hoffa's fat pad**
- ROM: Flexion 130 Extension 0
- No ligamentous laxity with Lachman's (firm endpoint), varus/valgus stress at 30° of flexion and posterior drawer
- Special Tests: **Clarks positive**, McMurray's and Thessaly both negative



Questions?

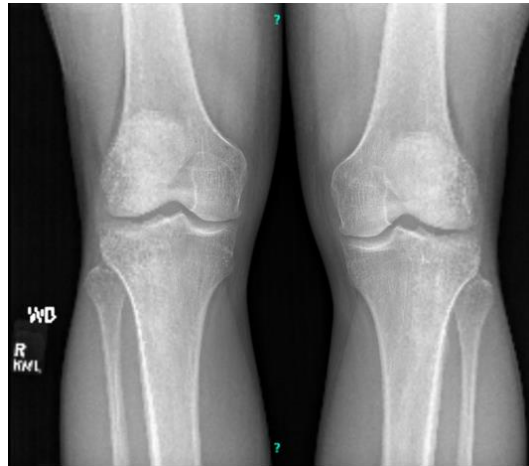DIFFERENTIAL DIAGNOSIS

**Proximal
Patellar
Tendinosis**

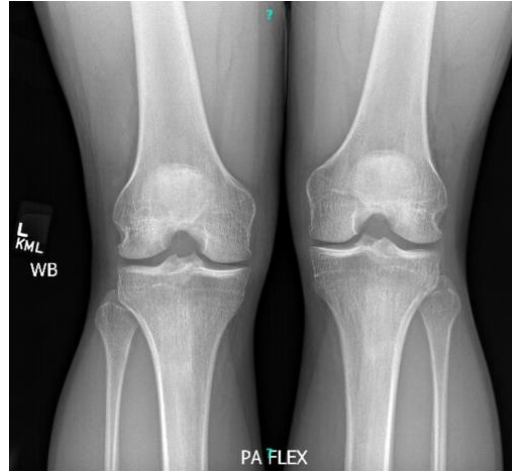**Infrapatellar
Fat Pad
Impingement**

**Patellofemoral
Pain
Syndrome**

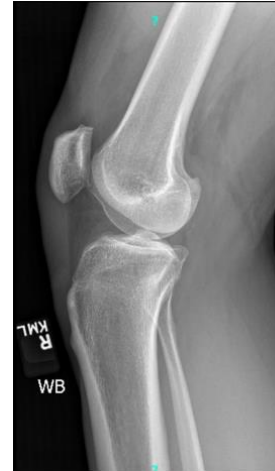Bilateral knee radiographs, with four views of the right knee



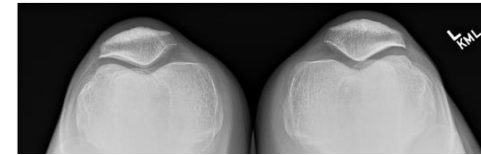
AP VIEW



PA FLEX VIEW



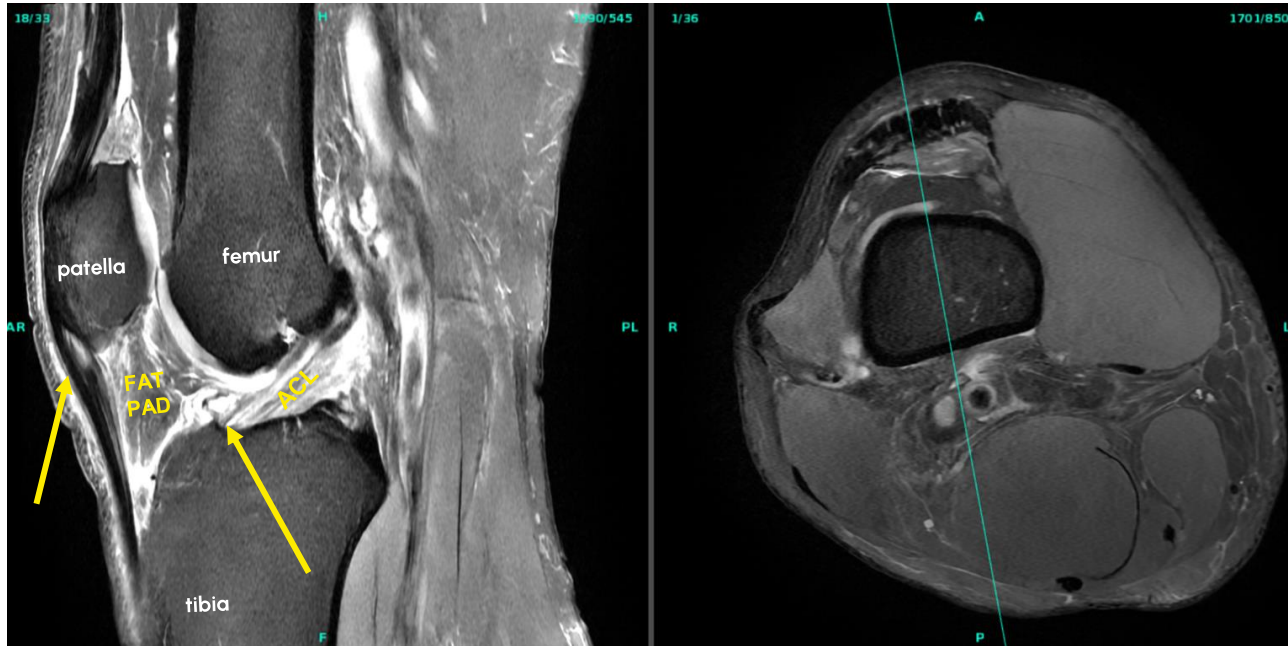
LATERAL

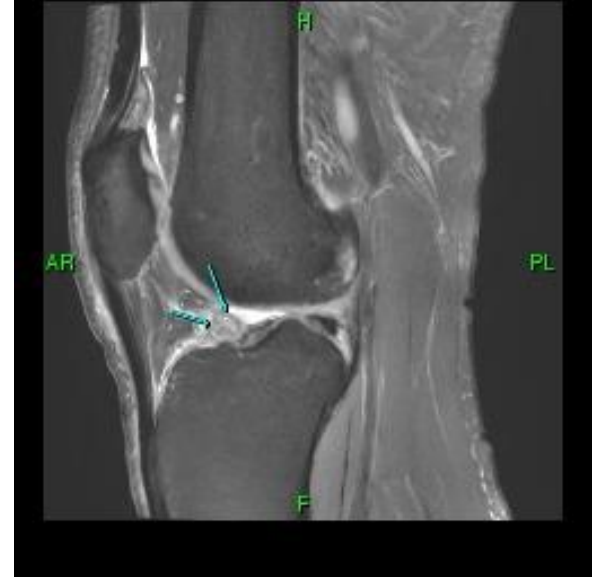
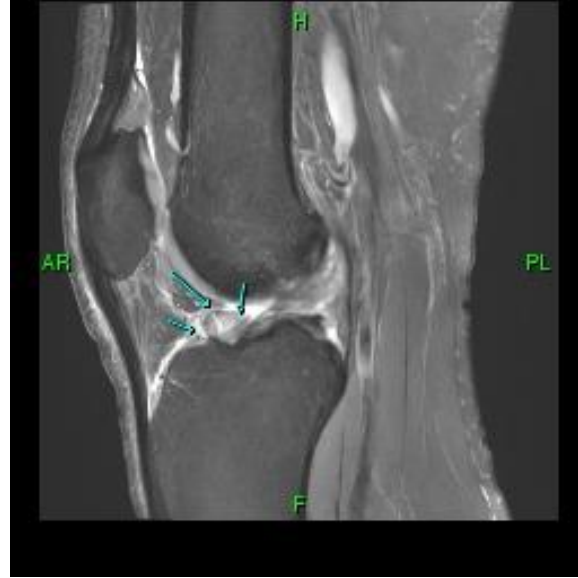
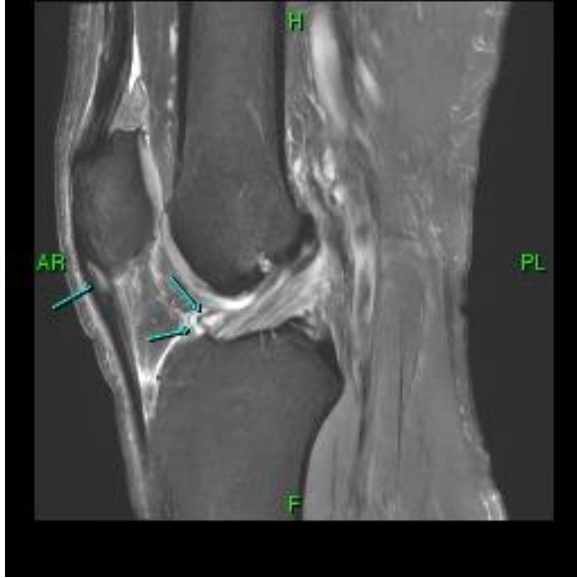AXIAL

**No fracture lucency,
dislocation or acute osseous
abnormality of the right or left
knee**

MRI right knee to rule out meniscus tear vs. osteochondral defect vs. tendinopathy





IMPRESSION:

- 1. Mild patellar tendinosis at its patellar attachment.**
- 2. Mixed cystic and fibrotic changes at the posterior inferior aspect of the infrapatellar fat pad consistent with focal Hoffa disease.**
- 3. Mild edema and convexity of the quadriceps fat pad, a finding of questionable significance but which which may be seen with fat pad impingement.**

Final Working Diagnosis:

Proximal patellar tendinosis with
infrapatellar fat pad
impingement and concomitant
patellofemoral pain syndrome.

INITIAL MANAGEMENT

ULTRASOUND GUIDED R KNEE ACP ARTHREX INJECTION



4 ML

4 ML

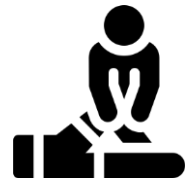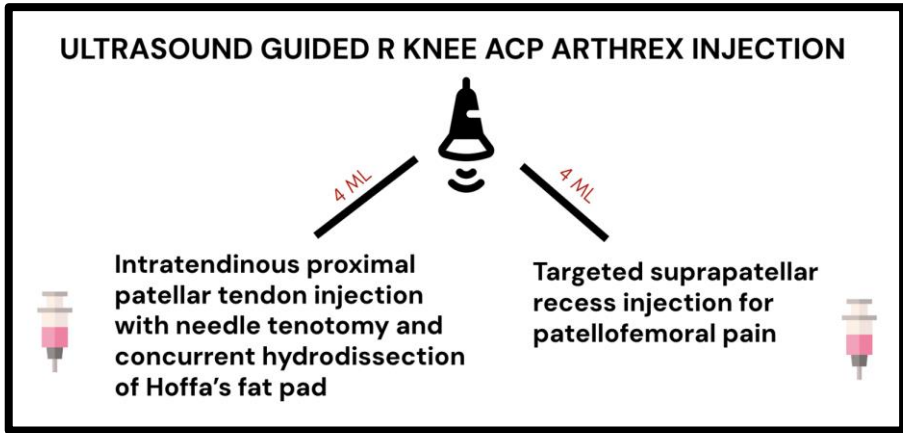


Intratendinous proximal patellar tendon injection with needle tenotomy and concurrent hydrodissection of Hoffa's fat pad

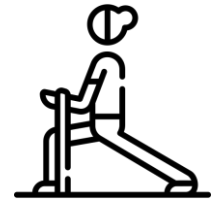Targeted suprapatellar recess injection for patellofemoral pain



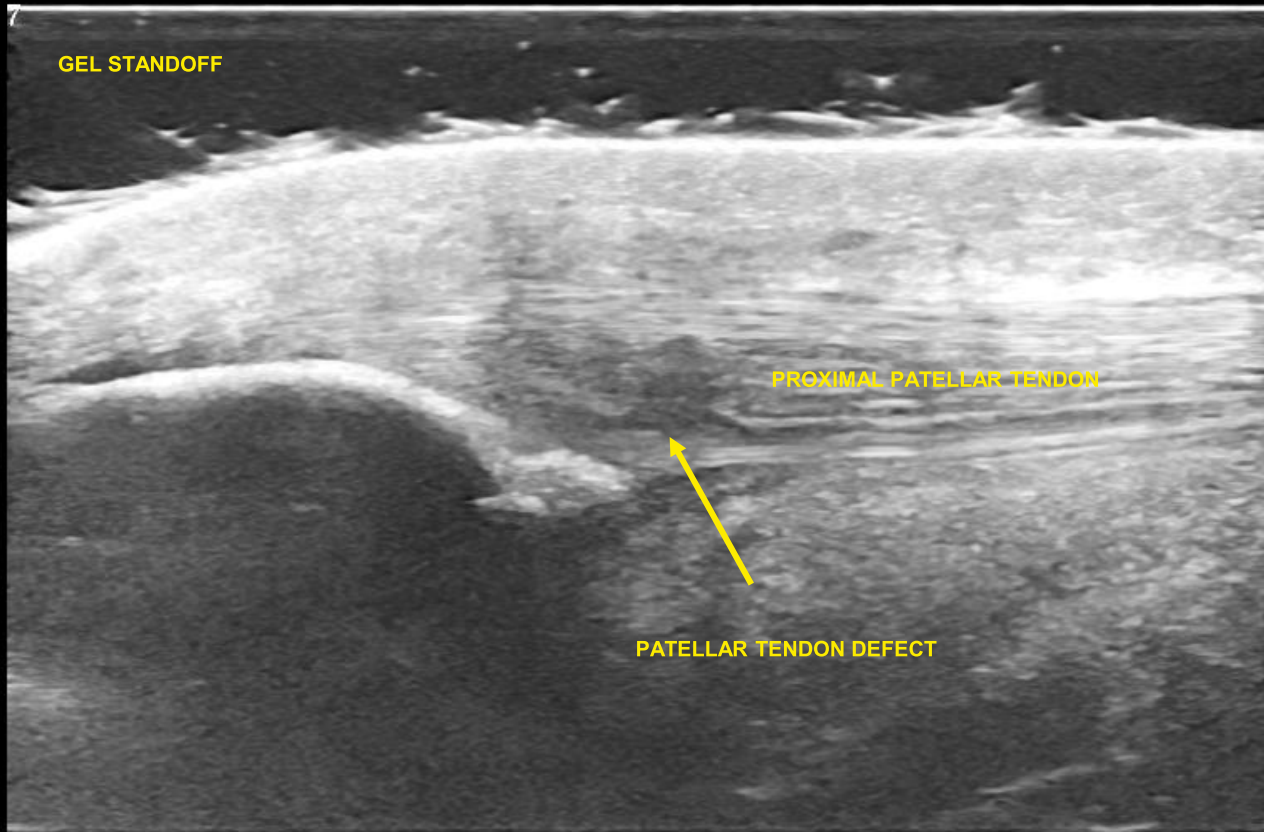
INITIAL MANAGEMENT



Formal Physical Therapy, Home Exercises, Activity Modification



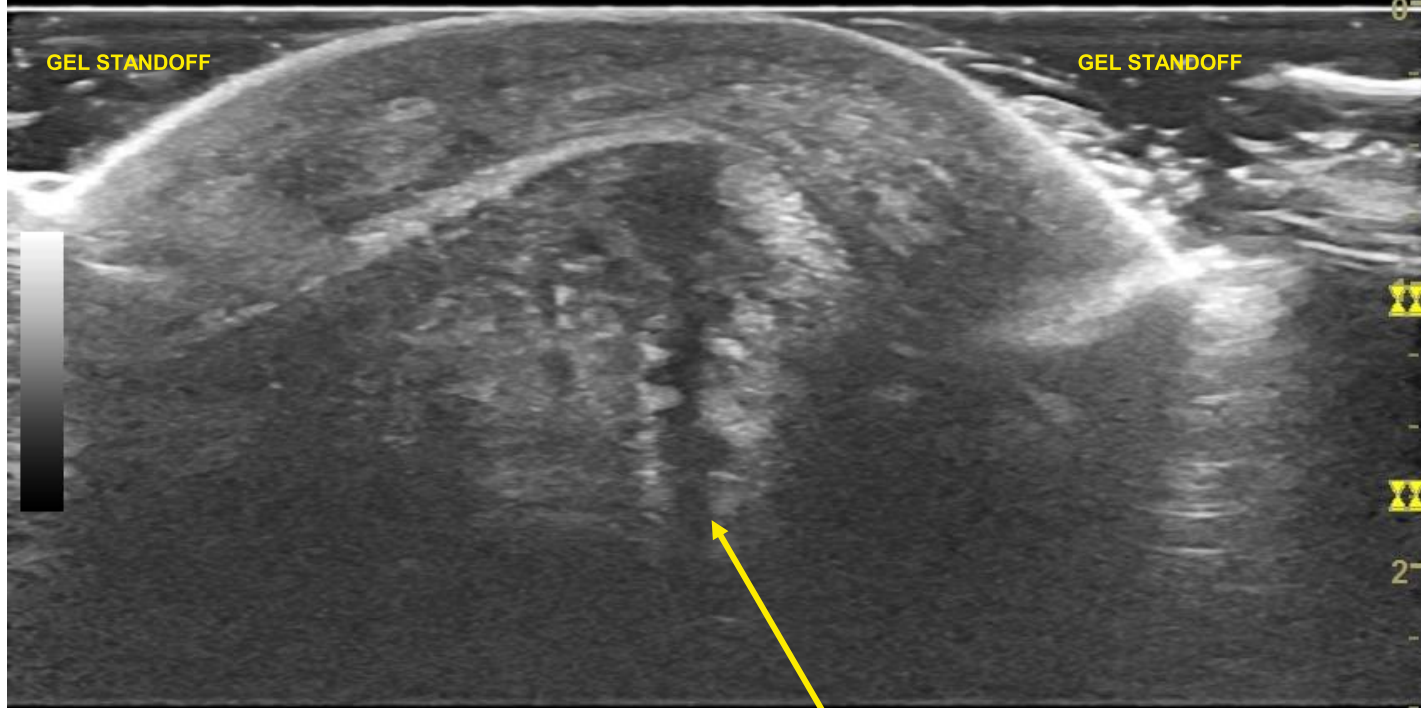
Long Axis Patellar Tendon



PROXIMAL

DISTAL

Short Axis Patellar Tendon



GEL STANDOFF

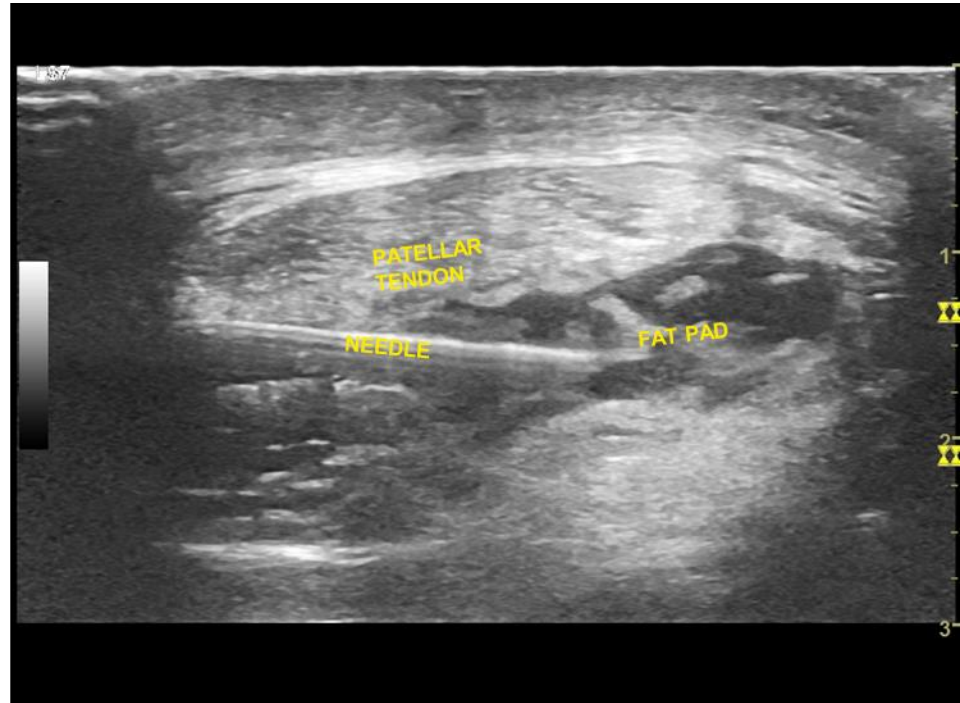
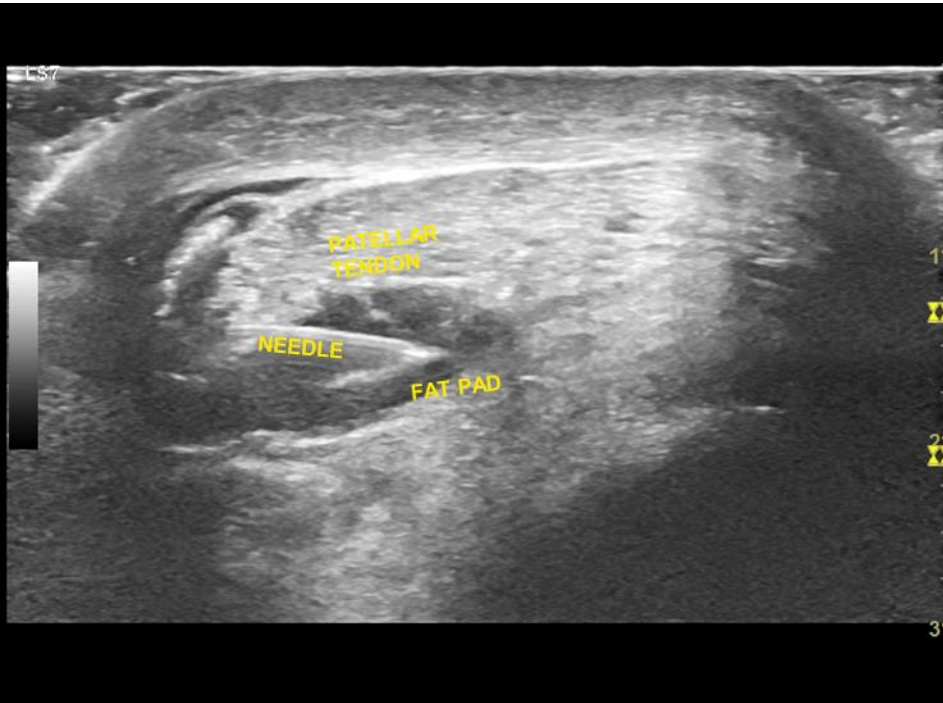
GEL STANDOFF

LATERAL

MEDIAL

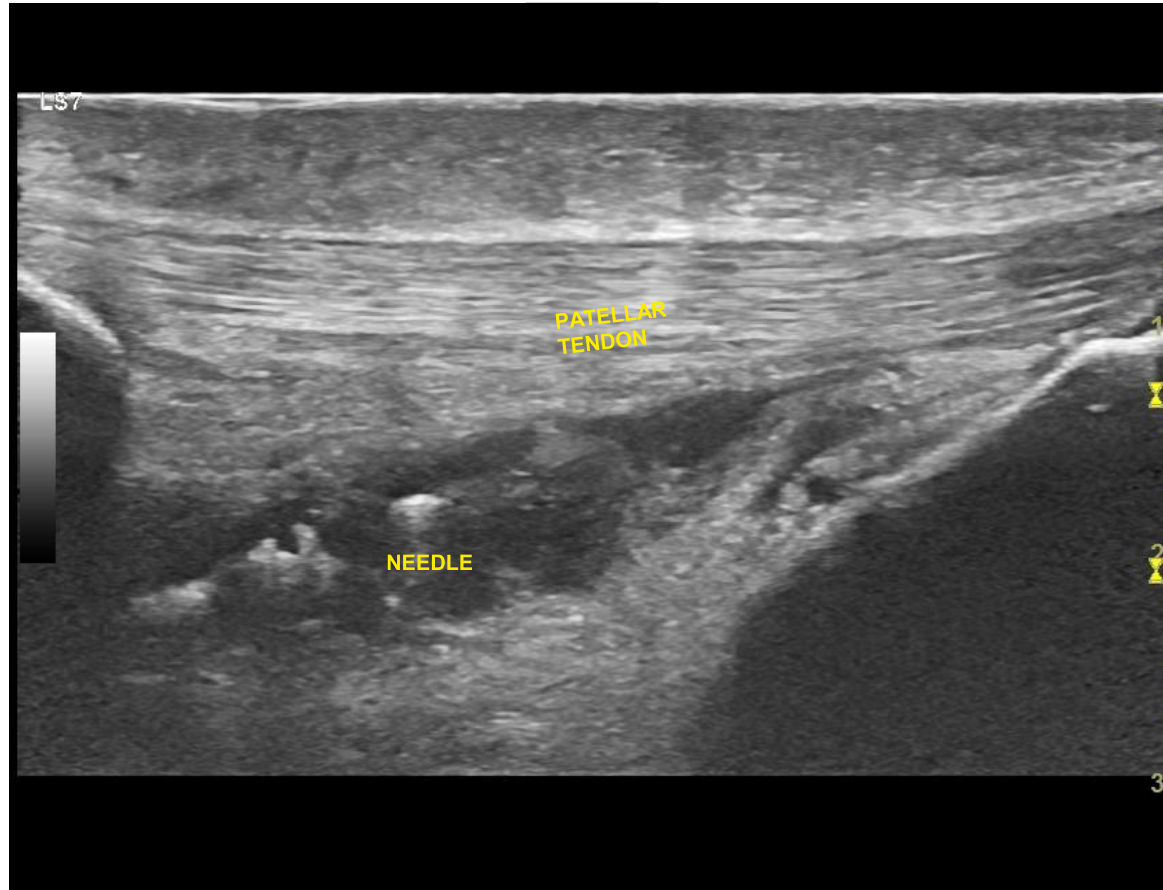
INTERSTITIAL TEAR PROXIMAL
PATELLAR TENDON

Hydrodissection of Infrapatellar Fat Pad* - Short Axis

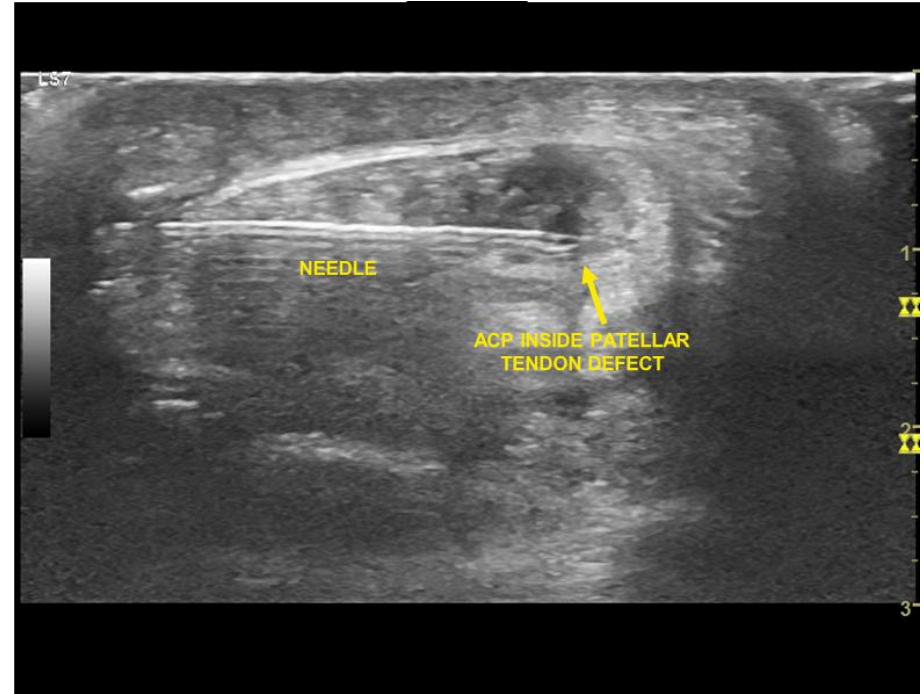
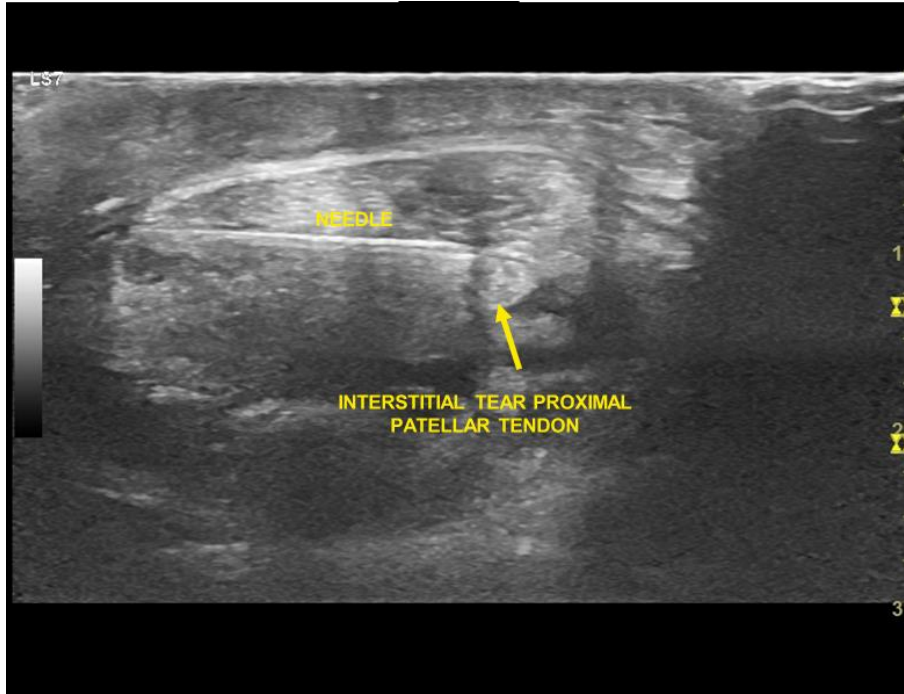


***Technique obtained from Hall et al (2016)

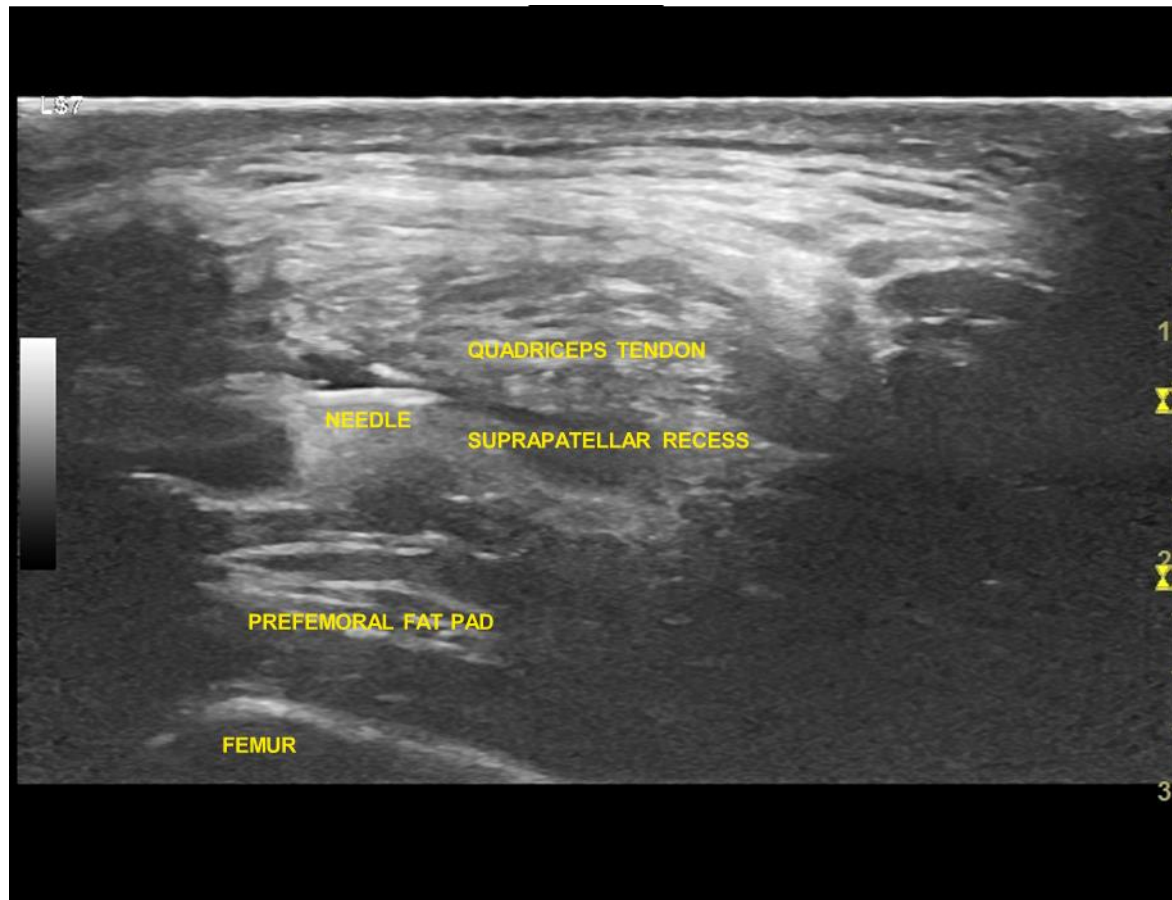
Hydrodissection of Infrapatellar Fat Pad - Long Axis



TENOTOMY / ACP INJECTION OF PATELLAR TENDON



ACP INJECTION SUPRAPATELLAR RECESS



Follow up three months later:

Patient remained active in PT/ HEP. He noted significant relief of pain in the region of the patellar region and patellofemoral compartment.

OUTCOME – 6 MONTH UPDATE FROM HIS PT

- “ He had relief post injection along the knee and **currently his symptoms along the patellar tendon are pretty diminished.**
- I will say he is better able to perform knee based movements and load the knee compared to prior receiving the injection.
- He reported that he is still having discomfort but notes that it is more superior along the distal quadriceps. I am still seeing him. He has been participating in crossfit and general lifting - but states that he is not able to push it as heavy as he wants to .”

QUICK DISCUSSION

Osteoarthritis and Cartilage 18 (2010) 876–882

Osteoarthritis and Cartilage



Review

The infrapatellar fat pad should be considered as an active osteoarthritic joint tissue: a narrative review

S. Clockaerts ††*, Y.M. Bastiaansen-Jenniskens ‡, J. Runhaar ‡, G.J.V.M. Van Osch ‡, J.F. Van Offel †, J.A.N. Verhaar ‡, L.S. De Clerck †, J. Somville †

† University of Antwerp, Department of Medicine, Belgium

‡ Erasmus MC, University Medical Center Rotterdam, The Netherlands

Thank you!

References:



 **SINAI HOSPITAL**

A LifeBridge Health Center

Rehabilitation Institute

ABBEL - Anil Bhavne Biomechanics & Engineering Labs Research Division

CARE BRAVELY



UNIVERSITY of MARYLAND
SCHOOL OF MEDICINE





PM R 8 (2016) 593-596



www.pmrjournal.org

Case Presentation

Ultrasound-Guided Scraping for Chronic Patellar Tendinopathy: A Case Presentation

Mederic M. Hall, MD, Sathish Rajasekaran, MD