

Challenges of Dry Beriberi: A Case of Multidisciplinary Rehabilitation in a Patient with Thiamine Deficiency Causing Sensorimotor Axonal Polyneuropathy

Matthew Bankert, DO; Christine Yunjae Wang, MD; Jordan Wickstrom, PhD; Sarah A. Eby, MD

ABBEL Research Division, Rehabilitation Institute at Sinai, Sinai Hospital of Baltimore, Baltimore MD

Introduction

- Thiamine (Vitamin B1) plays a crucial role in glucose metabolism and other biochemical pathways.¹
- Vitamin B1 deficiency can cause detrimental effects on the cardiovascular and neurological systems.
- Dry beriberi is one of the clinical disorders associated with this vitamin deficiency.²
- Symptoms of this disorder include distal sensory loss, paresthesia, muscle weakness, and fatigue.
- Onset of symptoms can be abrupt or take time, further complicating or delaying diagnosis.³

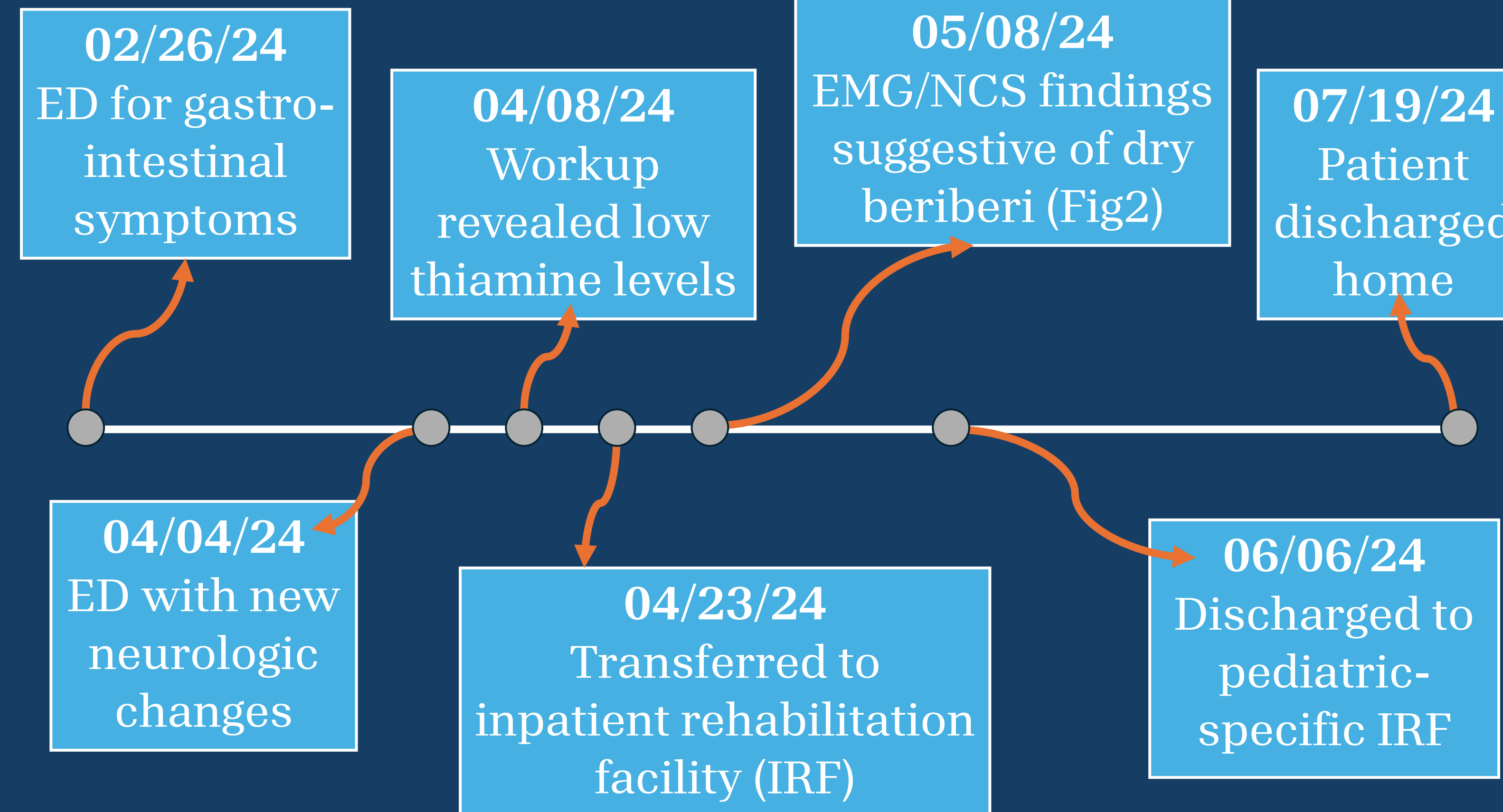
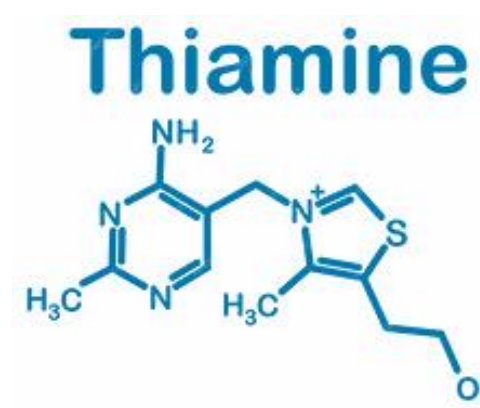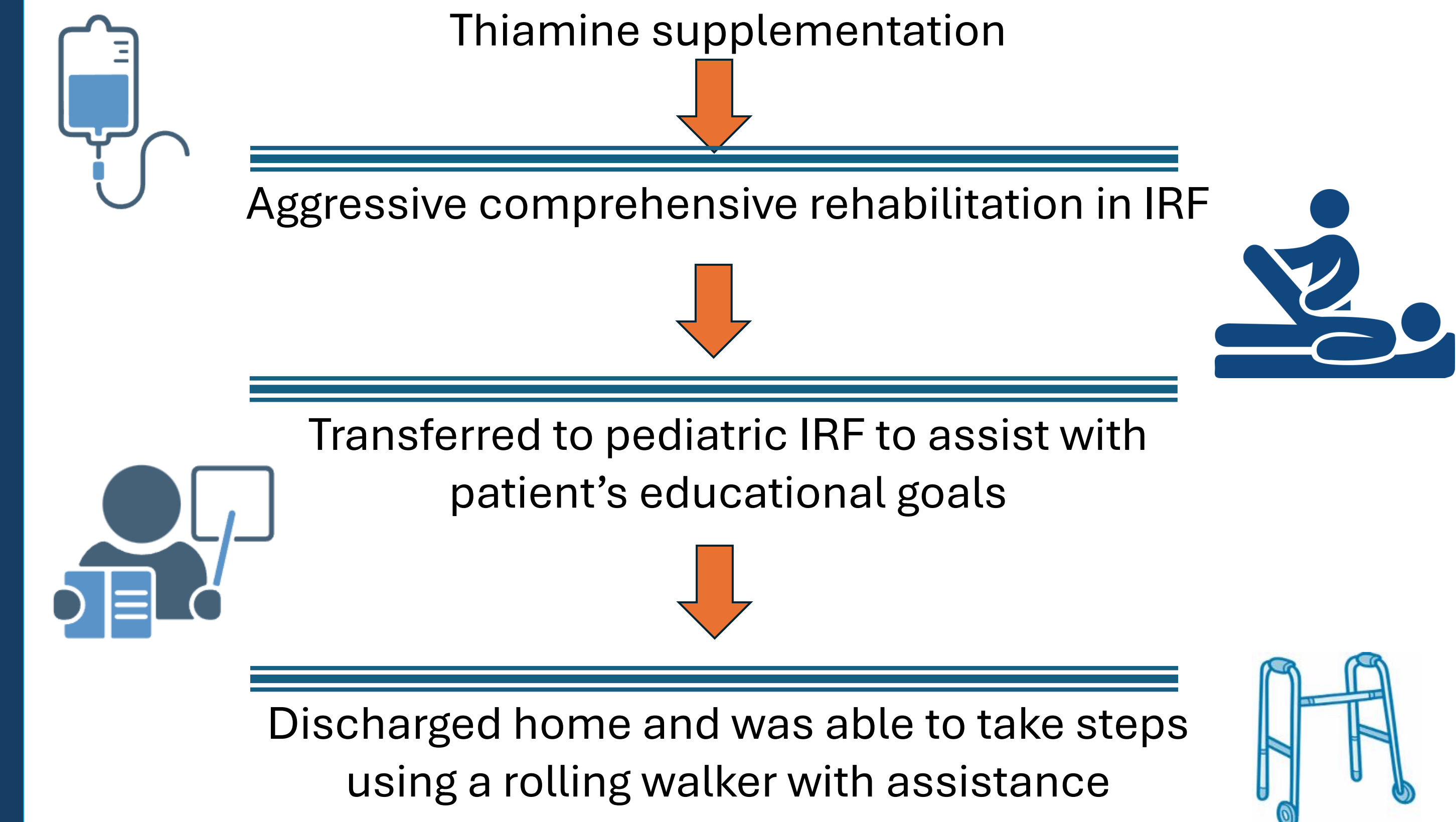


Figure 1 Patient symptom and recovery timeline.

Clinical Course



Case Description

Demographics

- 19 years old
- Female

Medical/Surgical History

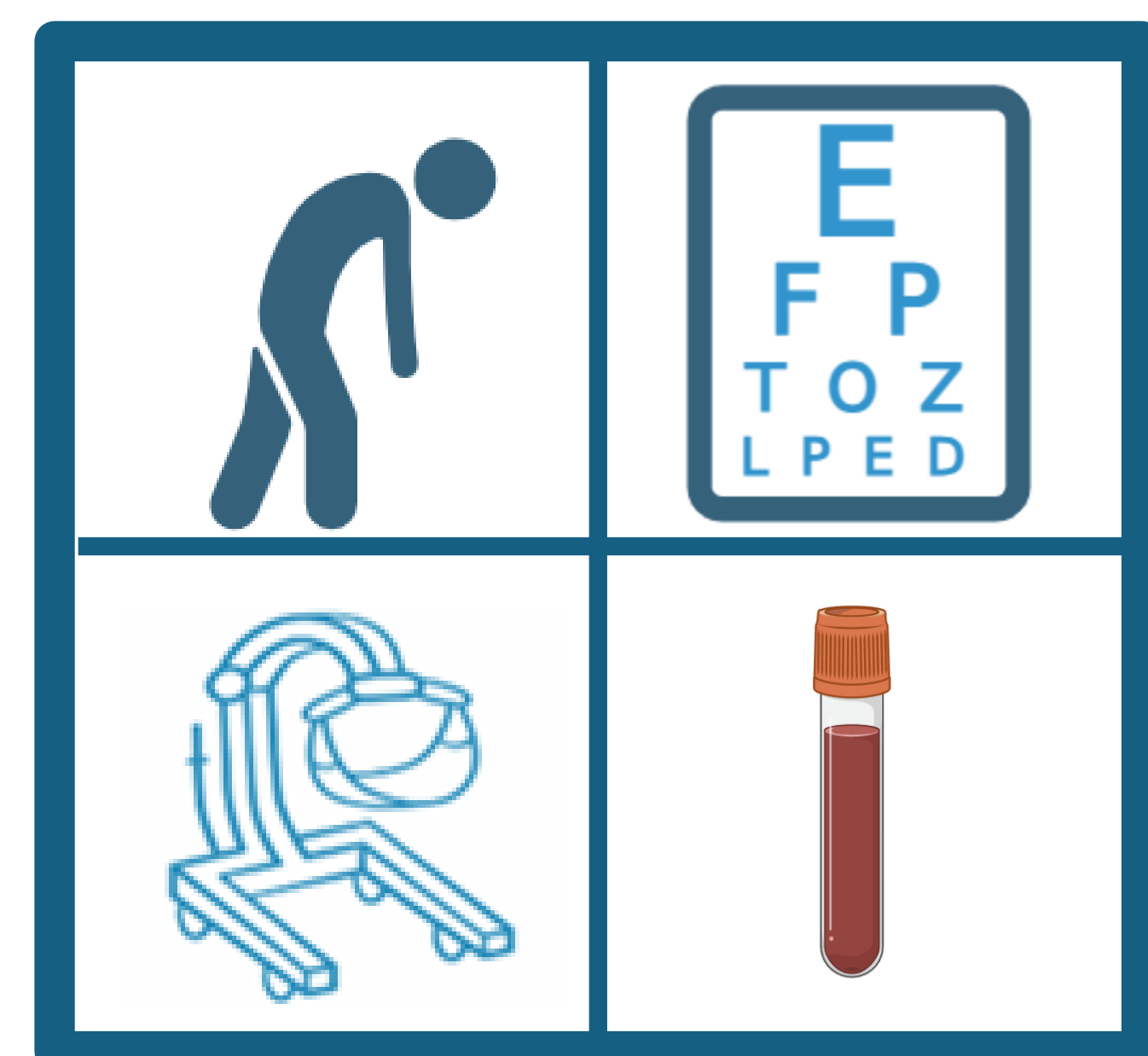
- Diabetes
- Obesity
- Slipped capital femoral epiphysis s/p repair

Symptoms

- 2-month history of nausea, vomiting, poor nutrition
- Vision changes
- Weakness
- Parasthesias

Physical Exam

- Weakness
- Abnormal light touch sensation in bilateral legs
- Absent reflexes



Strength Exam

Muscle Group	Strength (Bilateral)
Hip Flexors	2 / 5
Knee Extensors	2 / 5
Ankle Dorsiflexors	0 / 5
Ankle Plantarflexors	3 / 5

Diagnostics

- Low B1 levels at 27.8 nmol/L (normal low of 66.5-200)
- Negative Imaging (MRI brain, spine)
- Nerve Conduction Study (NCS) – see Figure 2

Results

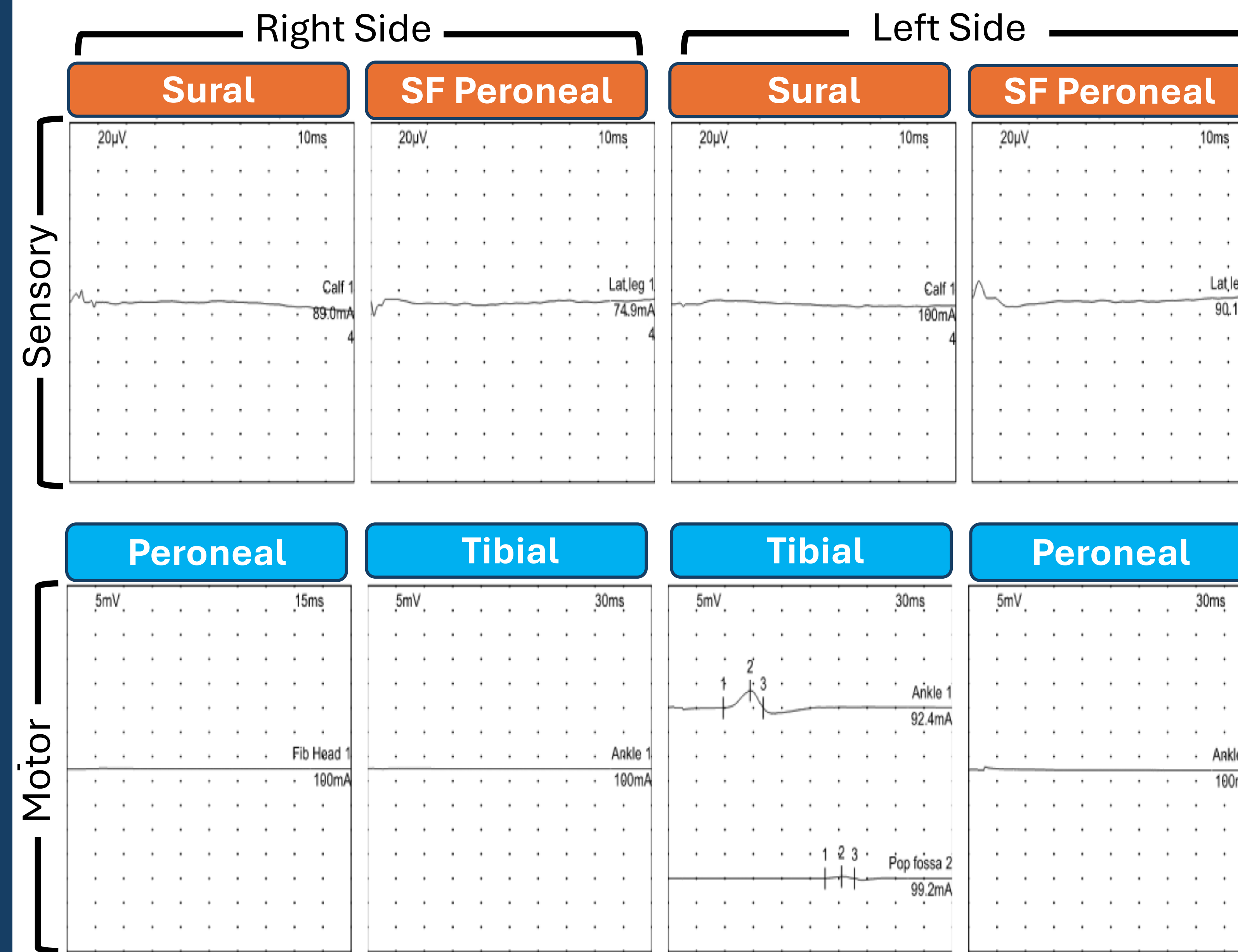


Figure 2

Patient's nerve conduction tests showed severe, length-dependent, largely symmetric, sensorimotor axonal polyneuropathy with evidence of marked acute denervation changes on electromyography.

Abbreviation: SF=superficial

Discussion

- The sensorimotor sequelae of dry beriberi can lead to severe disability.
- This case demonstrates that thiamine supplementation and medication alone is insufficient in providing appropriate care for patients with dry beriberi.
- A multidisciplinary team, including neurology, PM&R, nutrition, physical and occupation therapy, rehabilitation nursing, and psychology, were *vital* to the patient's recovery.

Conclusion

- Early recognition of thiamine deficiency and repletion is imperative; however, repletion alone is insufficient in providing appropriate care for patients with dry beriberi.
- A multidisciplinary approach is essential to appropriately diagnose and treat this condition^{4,5}

Primary Takeaway:

This case highlights the severity of functional deficits that can occur with dry beriberi and the necessity of a multidisciplinary approach in care to optimize recovery and quality of life



References