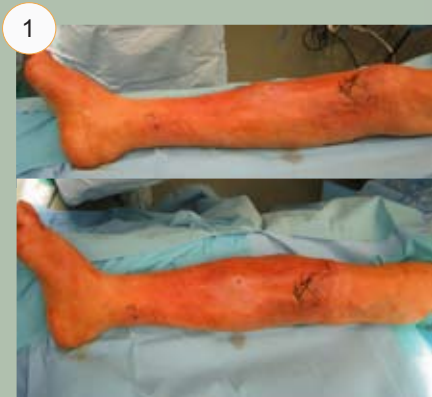
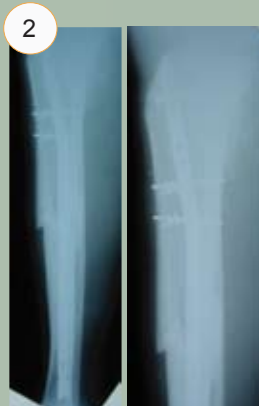
Cases 1 and 2

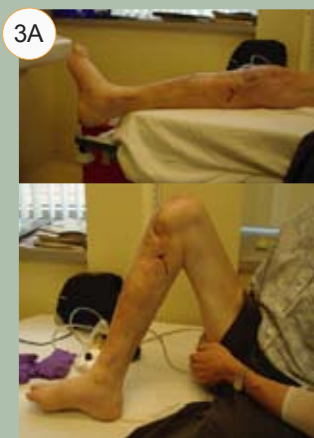Case 1



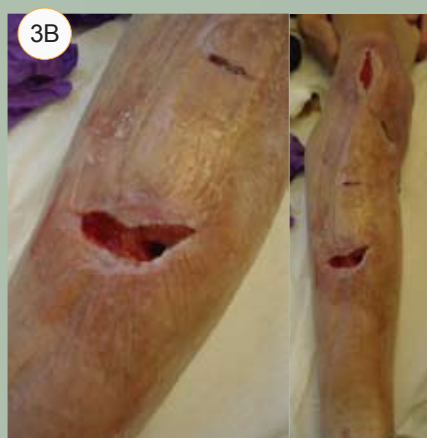1
Preoperative photo: 58-year-old male with diabetes and a segmental tibial shaft fracture treated with IM rod. Photo obtained 3 weeks after initial surgery. Patient has cellulitis and deep infection.



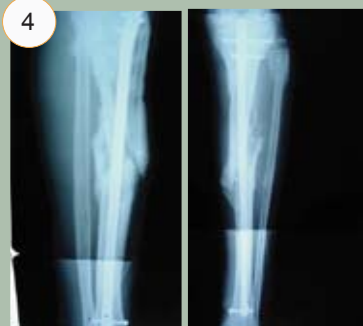2
Preoperative radiographs.



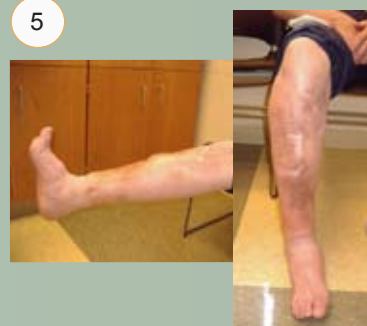3A
Two-week postoperative visit.



3B

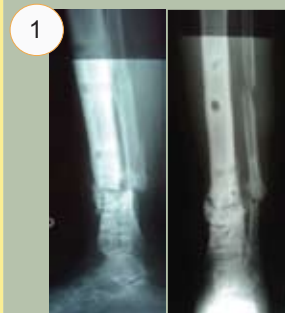

4
Three-month postoperative radiographs.

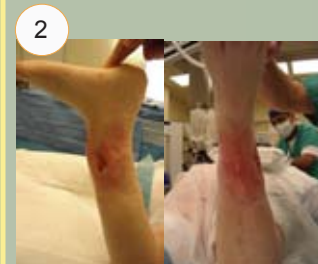

5
Two-year follow-up. Complete healing was achieved with no sign of infection.

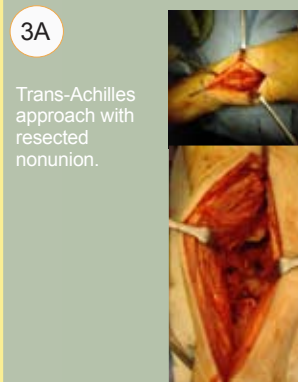Case 2



1
Preoperative radiographs: 60-year-old female with infected distal tibial nonunion, diabetes, and one-vessel leg. Previous Ilizarov treatment failed.

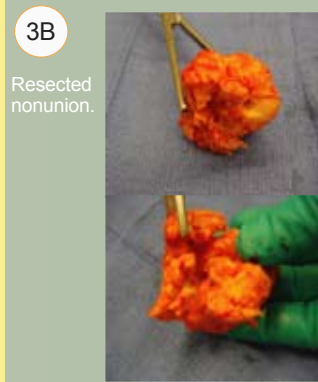

2
Preoperative clinical photo shows poor anterolateral soft tissue envelope.



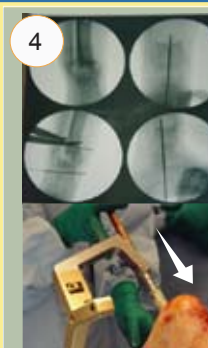3A

Trans-Achilles approach with resected nonunion.



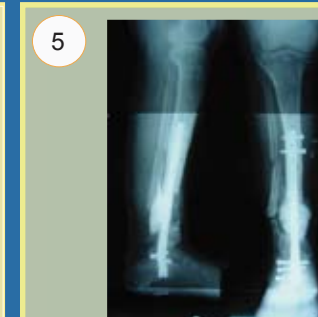
3B

Resected nonunion.



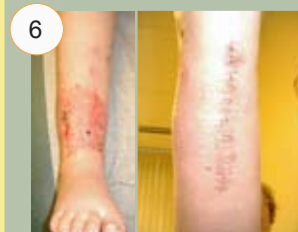4

Intraoperative fluoroscopic images and photo of rod insertion.



5

Six-month postoperative radiographs.



6

Trans-Achilles approach healed well and avoided anterior soft tissue envelope.

Three-year follow-up:
Still ambulatory on stable leg. No additional surgery was necessary.